



DATE PRESENTING CLINICAL SIGNS

History: Previously diagnosed with a VSD and mild LAE/LVE. Receiving enalapril. Doing well.

5/18/22

ECHOCARDIOGRAPHIC FINDINGS

2D, M-mode, and Doppler study.

PERFORMED BY:

Loetitia Saint-Jacques, RVT, LVT

Left atrial size is normal. The mitral valve is normal. Left ventricular wall thickness is normal. There is mild left ventricular dilation. Left ventricular systolic function is normal. There is Doppler evidence of left-to-right shunting through a perimembranous ventricular septal defect. The aorta and aortic valve appear normal, though there is mildly increased flow velocity in the ascending aorta, as well as mild aortic insufficiency. Right atrial and right ventricular dimensions are normal. The tricuspid is normal. The pulmonary artery and pulmonic are normal. No pericardial effusion or cardiac masses are seen.

INTERPRETED BY

Keith Blass, DVM, MS, DACVIM (Cardiology)

LA/Ao - 1.42 (prev. 1.64)
IVSd - 3.9 mm (prev. 3.4 mm)
LVPWd - 4.7 mm (prev. 3.4 mm)
LVIDd - 17.8 mm (prev. 17.3 mm)
LVIDs - 10.6 mm (prev. 10.3 mm)
FS - 40% (prev. 40%)
RA - 11.4 mm
LVOT - 1.85 m/s (prev. 2.21 m/s)
RVOT - 1.38 m/s (prev. 1.30 m/s)
VSD - 4.75 m/s (prev. 4.86 m/s)

PATIENT

Figero Perry

SPECIES

Feline

ASSESSMENT/RECOMMENDATIONS

Ventricular septal defect (VSD)

BREED

This examination demonstrates no progressive left-sided volume overload secondary to Figero's VSD. As such, Figero's current risk for the development of congestive heart failure and/or thromboembolic disease still appears to be low, and it is my hope that his disease will continue to be well-tolerated indefinitely, though careful monitoring for the development of clinical signs associated with these conditions is still recommended.

DSH

SEX

No change in therapy is recommended at this time.

MN

A recheck echocardiogram is recommended in 9-12 months. Thoracic radiographs are recommended if Figero experiences respiratory clinical signs.

AGE

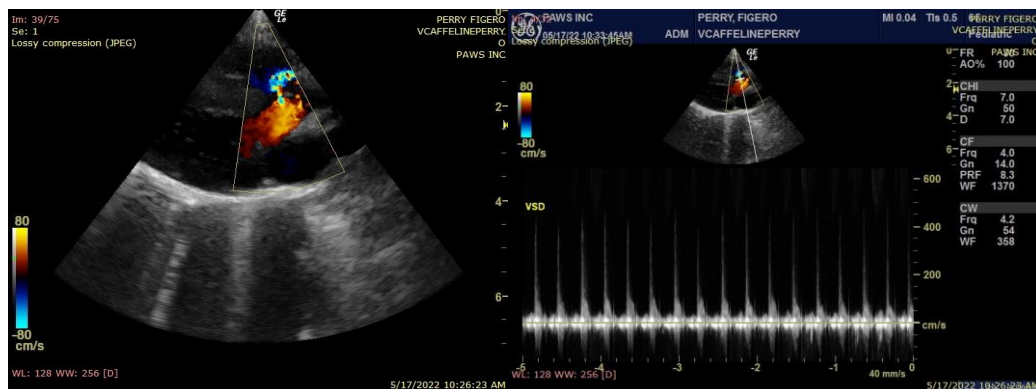
7 mo

WEIGHT

8.98 lb

HOSPITAL NAME

Nevada Humane Society



REFERRING VET

Dr. Matzke



DATE

5/18/22

The information and recommendations provided are based on the images presented by the referring veterinarian. No evaluation can be communicated regarding pathology that was not visible in the image/video clips provided.

PERFORMED BY:

Thank you for this referral. If the clinical or image interpretation does not parallel your findings or if I can be of any further assistance please contact me.

Loetitia Saint-Jacques, RVT, LVT

Keith Blass, DVM, MS, DACVIM (Cardiology)

INTERPRETED BY

KeithBlass@gmail.com
631-804-5754

Keith Blass, DVM,
MS, DACVIM
(Cardiology)

PATIENT

Figero Perry

SPECIES

Feline

BREED

DSH

SEX

MN

AGE

7 mo

WEIGHT

8.98 lb

HOSPITAL NAME

Nevada Humane
Society

REFERRING VET

Dr. Matzke